BASELINE VITAL SIGNS AND SAMPLE HISTORY

OBJECTIVES

- 1-4.1 Identify why and when baseline vital signs and SAMPLE history must be done with at least 80% accuracy.

OBJECTIVES

- Anatomical Terms
- Body systems
- Baseline Vital Signs
- SAMPLE History

Anatomical Terms

- Normal anatomical position
  - Person standing, facing forward, palms facing forward
- Normal anatomical planes
  - Midline
  - Mid-axillary

Anatomical Terms

- Torso
- Medial
- Lateral
- Proximal
- Distal
- Superior
- Inferior
- Anterior
- Posterior
- Right/Left

Anatomical Terms

- Mid-clavicular
- Bilaterally
- Dorsal
- Ventral
- Plantar
- Palmer
- Prone
- Supine
- Fowlers
- Trendelenburg/ Shock

The Skeletal System

- Function
  - Gives body shape
  - Protects vital organs
  - Provides body movement
- Skull
  - Houses/ protects brain
- Face

The Skeletal System

- Spinal column
  - Cervical-7
  - Thoracic-12
  - Lumbar-5
  - Sacral-5
  - Coccyx-4

The Skeletal System

- Thorax
  - 12 pair of ribs
- Sternum
  - Manubrium
  - Body
  - Xiphoid process

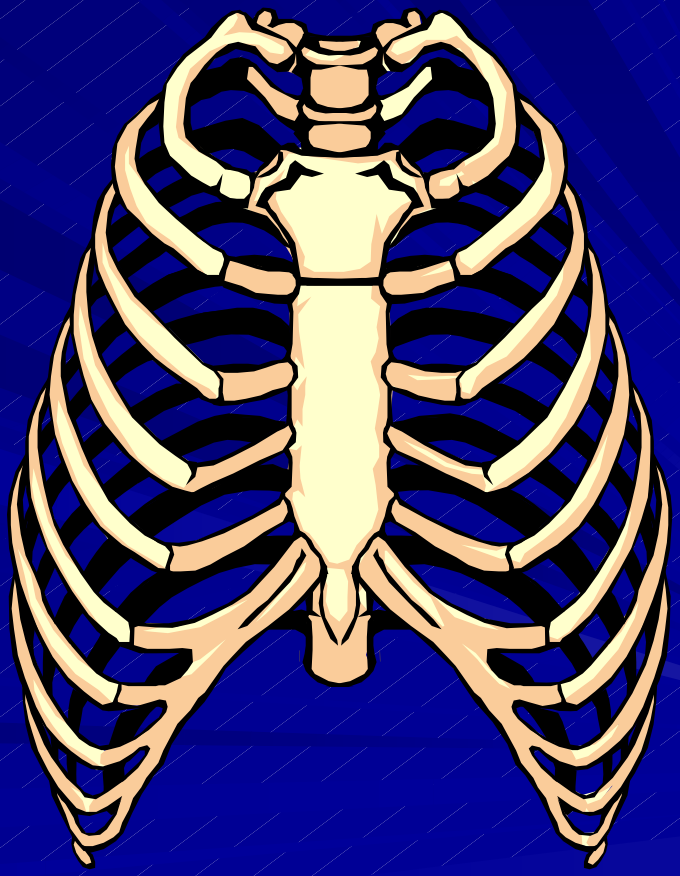

The Skeletal System

- Pelvis
  - Illiac crest - wings of pelvis
  - Pubis - anterior of pelvis
  - Ischium - inferior of pelvis
- Lower extremities

The Skeletal System

- Upper extremities
- Joints
  - Where bones connect to other bones
  - Types
    - Ball and socket
    - Hinged

The Respiratory System

- Nose/mouth
- Pharynx
- Epiglottis
- Trachea

The Respiratory System

- Larynx
  - Contains voice box
- Cricoid cartilage
  - Lower most cartilage of the larynx

The Respiratory System

- Bronchi
- Lungs
- Diaphragm
  - Major muscle for breathing

The Process

- Inhalation (active)
  - Diaphragm contracts
    - Increases the size of the thoracic cavity

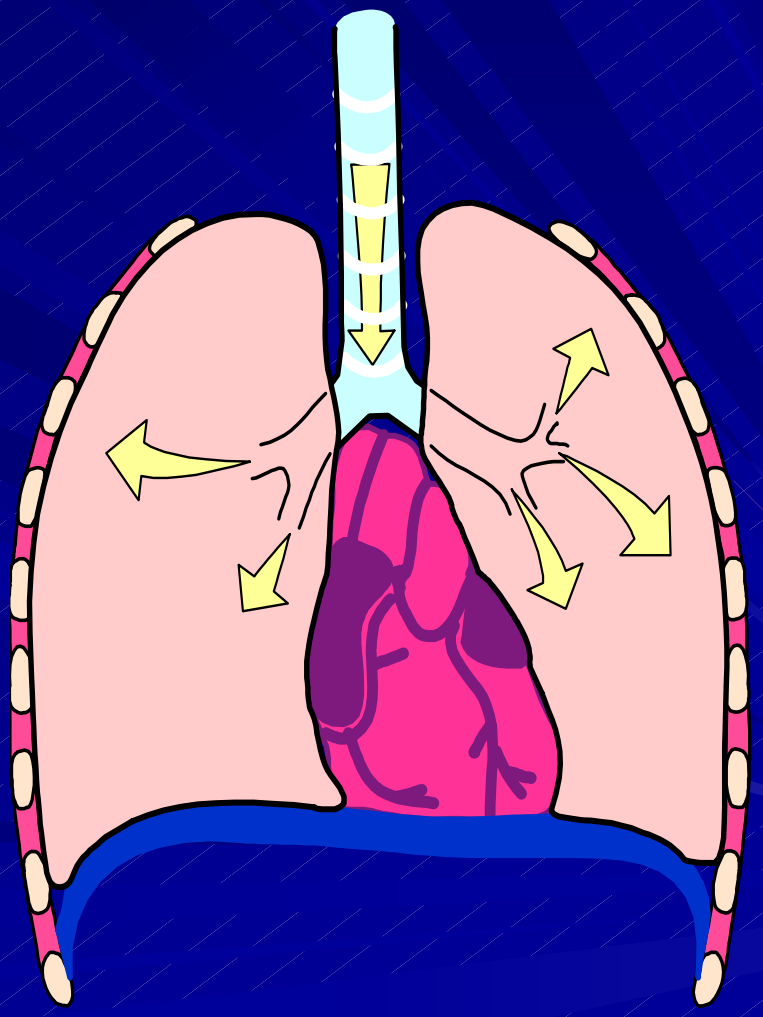

The Process

- Exhalation (passive)
  - Diaphragm relaxes
    - Decreasing the size of the thoracic cavity

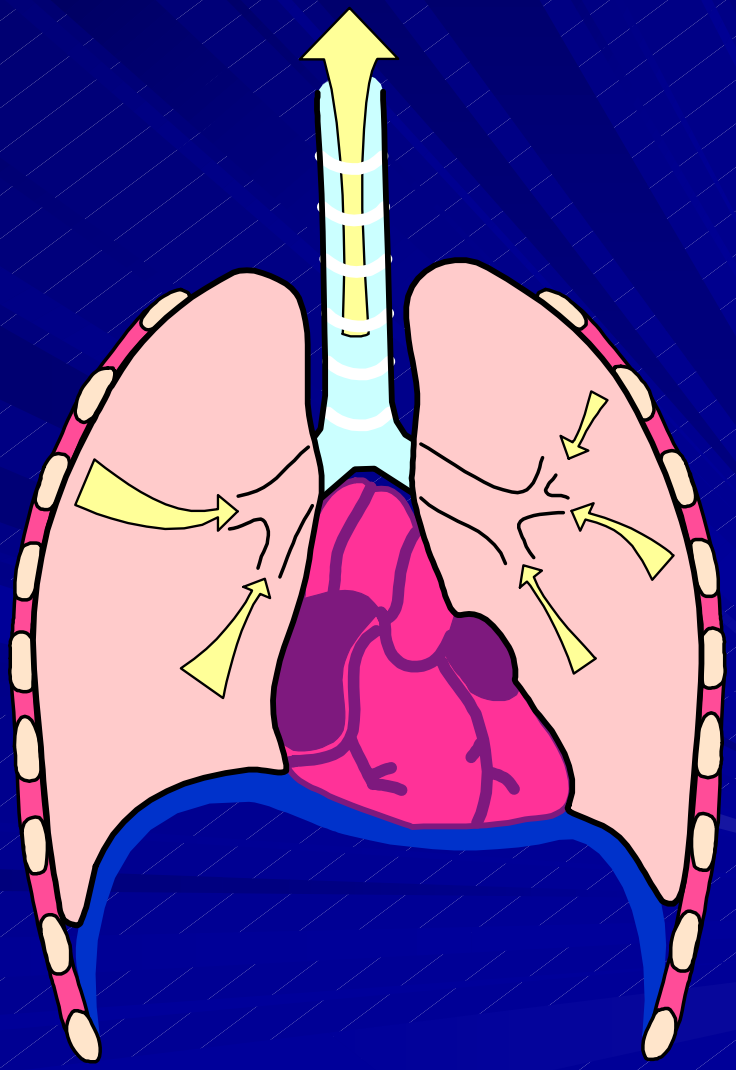

Respiratory Physiology

- Alveolar/Capillary/Cellular exchange
  - Oxygen rich air enters the alveoli on inspiration
  - Oxygen poor blood in the capillaries passes to the alveoli
  - Oxygen enters the capillaries as carbon dioxide enters the alveoli

Adequate Breathing

- Normal rate
  - Adult 12-20/min
  - Child 15-30/min
  - Infant 25-50/min
- Rhythm
  - Regular

Adequate Breathing

- Quality
  - Breath sounds
    - Present and equal
  - Chest expansion
    - Adequate and equal
  - Effort of breathing

Adequate Breathing

- Depth (Tidal Volume)
  - Average breath 500-800 ml

Inadequate Breathing

- Rate
- Quality
  - Breath sounds
    - Diminished or absent
  - Chest expansion
    - Unequal or inadequate
  - Increased breathing effort

Inadequate Breathing

- Depth
- Skin
  - Cyanotic
  - cool/clammy
- Muscle retractions
  - Often seen in children

Inadequate Breathing

- Nasal flaring
  - Often seen in children
- Agonal Respiration's
  - Gasping respirations
- See-saw respirations in infants
- Altered mental state

Infant/Child Anatomy Considerations

- Mouth/nose
- Pharynx
- Trachea (windpipe)
- Cricoid cartilage
- Diaphragm

The Circulatory System

- Heart
  - Right atrium
    - Receives deoxygenated blood from body
  - Left atrium
    - Receives blood from the lungs

The Circulatory System

- Right ventricle
  - Pumps blood to lungs
- Left ventricle
  - Pumps blood to the body

The Circulatory System

- Valves
  - Prevents backflow of blood
- Cardiac conductive system
  - Specialized tissue

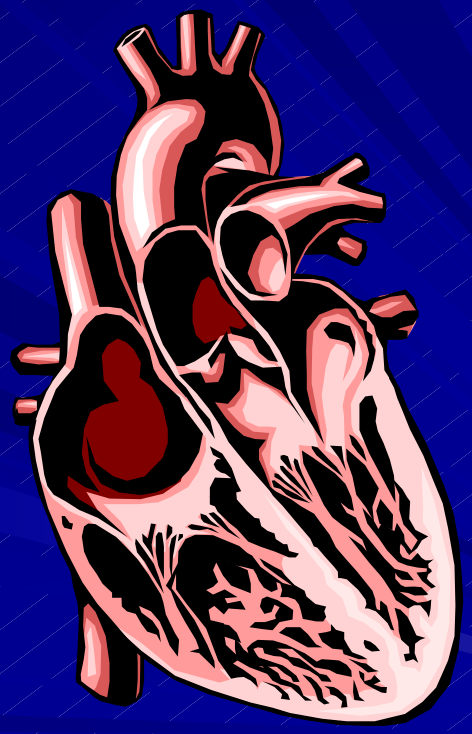

The Circulatory System

- Arteries – carry blood away from the heart
  - –Coronary arteries
  - –Aorta
  - –Pulmonary
  - –Carotid

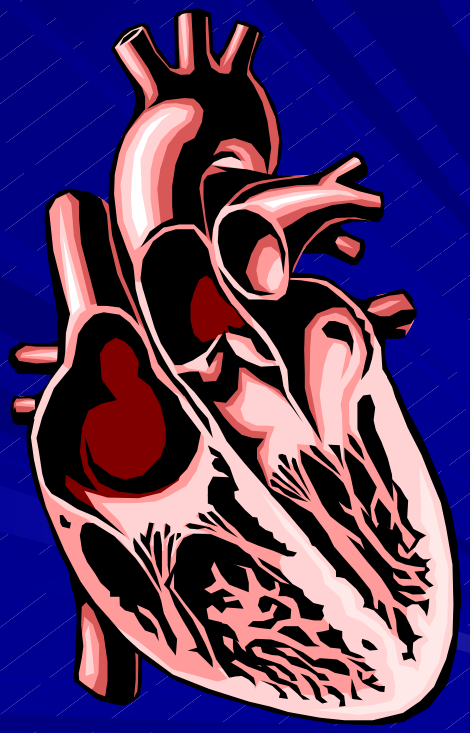

Arteries

- Femoral
- Radial
- Brachial
- Posterior tibial
- Dorsalis pedis

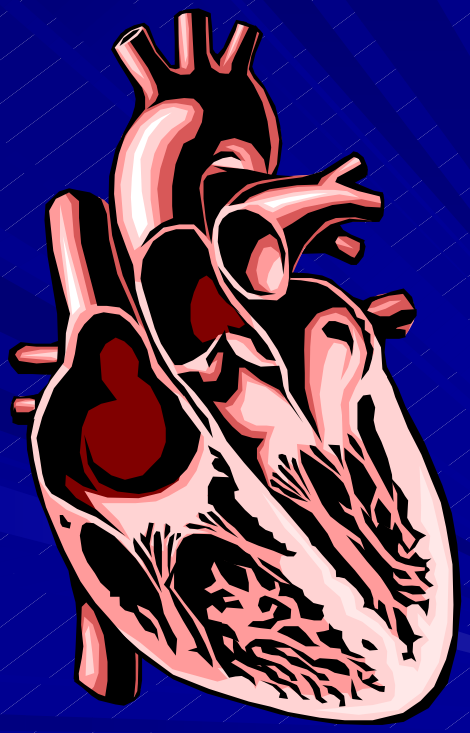

The Circulatory System

- Arteriole
  - Smallest branch of an artery
  - Leading to capillary

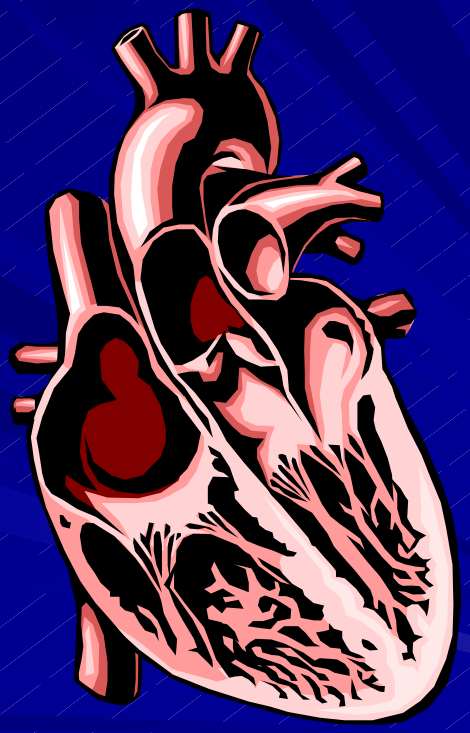

The Circulatory System

- Capillaries
  - Tiny blood vessels
  - Connect arterioles to venules
  - Allow for the exchange of nutrients and waste at the cellular level

The Circulatory System

- Venule
  - Smallest branch of a vein leading to the capillaries

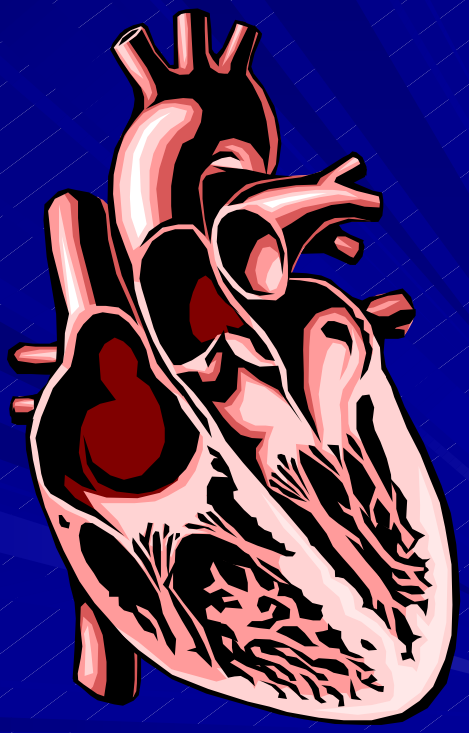

The Circulatory System

- Veins - vessels that carry blood back to the heart
  - –Pulmonary vein
  - –Venae cavae
    - Superior
    - Inferior

The Circulatory System

- Blood composition
  - RBC
    - Gives blood its color
  - WBC
    - Body's defense

The Circulatory System

- Plasma
  - Fluid that carries blood cells and nutrients
- Platelets
  - Form blood clots

The Circulatory System

- Physiology
  - Pulse
    - Left ventricle contracts sending a wave of blood through the arteries
    - Felt anywhere an artery passes between a bone and close to the skin

Pulse

- Peripheral pulses
  - Radial
  - Brachial
  - Dorsalis pedis

Pulse

- Central pulses
  - Carotid
  - Femoral

Blood Pressure

- Systolic
  - Pressure exerted against the walls of the artery when the left ventricle contracts
- Diastolic
  - Pressure exerted against the walls of the artery when the left ventricle is at rest

Physiology

- Hypoperfusion
  - Inadequate circulation
  - Also known as shock

Hypoperfusion
Signs and symptoms

- Pale
- Cyanotic
- Cool, clammy skin
- Rapid, weak pulse
- Restlessness
- Anxiety/mental dullness
- Nausea/vomiting
- Reduction in blood volume

Physiology

- Perfusion
  - Circulation of blood through an organ or structure
  - Delivers oxygen and nutrients to cells, and removal of waste products
  - Hypoperfusion = inadequate circulation

The Musculoskeletal System

- Function
  - Gives body shape
  - Protects internal organs
  - Provides for movement

The Musculoskeletal System

- Types
  - Voluntary
    - Skeletal
  - Involuntary
    - Smooth
  - Cardiac
    - Automaticity

The Nervous System

- Function
  - Controls the voluntary and involuntary activity of the body

The Nervous System

- Components
  - Central
  - Peripheral
    - Sensory
    - Motor

Skin

- Function
  - Protection
  - Temperature regulation
  - Sensation

Skin

- Layers
  - Epidermis
  - Dermis
  - Subcutaneous layer

Endocrine System

- Function
  - Secretes chemicals
    - insulin
- Responsible for regulating body activities and functions

Vital Signs - Breathing

"Rate and Quality 30 X 2"

- Rate
  - Adult 12-20/min
  - Child 15-30/min
  - Infant 25-50/min
- Quality
  - Normal
  - Shallow
  - Labored
  - Noisy

Vital Signs - Pulse

- Where
- Rate
- Quality
  - –Strong/weak
  - –Regular/irregular

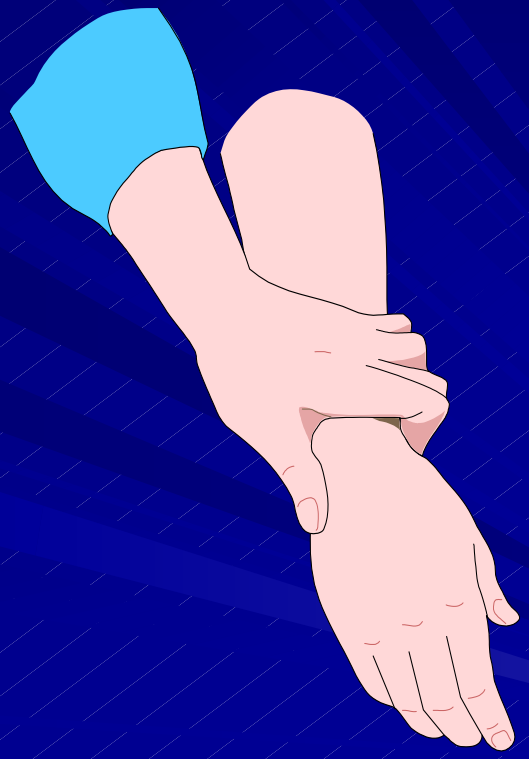

Vital Signs – Skin Color

- Where
  - Nail beds
  - Oral mucosa
  - Conjuctiva
- Normal Skin Color
  - Pink

Vital Signs – Skin Color

Abnormal skin colors

- Pale
  - White
  - Ashen
  - Grayish
- Flushed
  - Red
- Cyanotic
  - Blue- gray
- Jaundice
  - Yellow

Skin Temperature

- Use back of your hand
- Normal vs. abnormal
- Consider environmental conditions
  - Hot
  - Cool
  - Cold

Skin Condition

- Normal
  - Dry
- Abnormal
  - Wet
  - Moist
  - Dry

Vital Signs - Skin

- Capillary Refill
  - Use in infants and children
  - Normally < 2sec
  - Not valid in cold environments

Vital Signs – Pupils

- Dilated
- Normal
- Constricted
- PEARRL

Pupils
Equal And
Round
React to
Light

Vital Signs – Blood Pressure

- Systolic pressure
  - Measurement of the pressure exerted against the walls of the arteries during contraction of the heart

Blood Pressure

- Diastolic pressure
  - Represents the pressure exerted against the walls of an artery while the left ventricle is at rest

Blood Pressure

- Auscultation
  - Using a stethoscope to listen for systolic and diastolic sounds

Blood Pressure

- Palpation
  - In certain situations, the systolic pressure may be measured by feeling for return of pulse with deflation of the cuff

Blood Pressure

- Blood pressure should be measured in all patients older than 3 years old
- Under 3 years old
  - General assessment is more important than vital signs

Vital Signs - Reassessment

- Every 15 minutes in stable patients
- Every 5 minutes in unstable patients
- Also after every medical intervention

- **S** -- Signs/symptoms
- **A** -- Allergies
- **M**-- Medications
- **P** -- Pertinent past history
- **L** -- Last oral intake
- **E** -- Events leading to the illness or injury

REVIEW

- 1-4.1 Identify why and when baseline vital signs and SAMPLE history must be done with at least 80% accuracy.

REVIEW

- Anatomical Terms
- Body systems
- Baseline Vital Signs
- SAMPLE History